



## Interesting case report

### Cutaneous metastases from primary carcinoma larynx

#### - A rare presentation

Ramesh Aravamuthan, Ratnavel Gurusamy, Rajendrabose, Aarthi Barburam Krishna, Arun Prasath

Palanisamy

Stanley Medical College

#### Abstract:

The incidence of secondary cutaneous deposits from squamous cell carcinoma larynx is very rare. We report a sixty nine year old male who was diagnosed with squamous cell carcinoma of larynx who was treated with radiotherapy and chemotherapy, presented with multiple grouped nodules over the neck in a zosteriform pattern. Even though nodular, plaque-like, exuberant growth and sclerodermoid skin metastases have been described in laryngeal carcinoma, metastases to the skin in a grouped pattern is uncommon with only one case reported so far in the literature. The possible hypothesised cause of dermatomal metastatic distribution may be secondary to perineural lymphatic invasion and invasion of dorsal root ganglia by malignant cells.

#### Case report :

A sixty nine year old man presented to our skin department with asymptomatic grouped raised skin lesion over left side of neck of two months duration. On probing his history, he was diagnosed as having tuberculous lymphadenopathy of right cervical nodes by fine needle aspiration cytology (FNAC) in November 2010 at chest clinic and was on category I ATT, with no improvement.

Subsequently he developed multiple swellings over left cervical region with FNAC showing metastatic squamous cell carcinoma. He suddenly developed stridor and landed in ENT department during October 2011. Laryngoscopy showed proliferative growth in right aryepiglottic folds, with fixed right vocal cord. He was diagnosed as a case of carcinoma larynx with metastases to cervical lymph nodes. Emergency tracheostomy was done for stridor and he was referred to radiotherapy department. He underwent chemotherapy and radiotherapy for one month with a total dose of 8000 RADS, receiving 250 RADS per day and was declared disease free.

The dermatological examination showed multiple, shiny, skin coloured and hyperpigmented grouped papules and nodules coalescing to form plaques distributed over left side of the neck, with upper margin extending into left submandibular and mandibular region and lower margin extending into clavicular, supraclavicular, presternal area with spill over lesion on the right side of the neck. Underlying skin is non tender, indurated, with prominent furrows (Figure 1). No fluid extrusion was seen on puncturing the nodule. General and systemic examinations were unremarkable. On investigation hemogram, renal and liver function test, skiagram chest, ultrasonogram abdomen, were normal. Histopathology revealed extensive invasion of dermis by groups of tumour cells (Figure 2). The tumour cells are similar to those in the primary growth and atypical in character with large, pleomorphic, hyperchromatic nuclei with halo (Figure 3). Epidermis is intact. These findings were consistent with diagnosis of cutaneous metastases from primary squamous cell carcinoma of larynx. Patient is now under palliative chemotherapy in medical oncology department.

#### **Discussion :**

Cutaneous metastases from carcinoma larynx are very rare. Distant metastases in squamous cell carcinoma of the larynx have an incidence of 6.5-7.2% and most commonly involve the lungs, liver, and bone. Metastases to the skin are exceedingly rare, particularly in a grouped pattern are uncommon. Internal malignancy may be associated with skin findings due to metastasis, direct spread of malignancy, exposure to carcinogen, paraneoplastic diseases and genetic syndrome with systemic carcinogenesis. In general skin metastases of squamous cell carcinoma to the head and neck are rare. Squamous cell carcinoma is responsible for 95% of the carcinoma of the larynx in adults and is the most common tumour in upper respiratory tract. This tumour originates from glottis (59%), supraglottis (40%) or infraglottis (1%) and generally spreads to regional lymph nodes or

through blood, to the pulmonary system. Skin metastases have rarely been described as multiple or solitary non tender firm nodules, plaques or exuberant granulation tissue in "stomal recurrence" after laryngectomy or sclerodermoid plaques. A literature review found eight cases of grouped zosteriform skin metastases from various primary sites<sup>[1]</sup>, only one case reported so far from carcinoma larynx<sup>[2]</sup>, where patient developed grouped skin metastases in shoulder from laryngeal squamous cell carcinoma who underwent total laryngectomy followed by radiotherapy. But in our case, because of inoperable nature of tumour patient underwent radiotherapy alone. Other areas of the body reported previously following squamous cell carcinoma of larynx were distal phalanges of left hand<sup>[3]</sup>, buttock, back in metastatic laryngeal carcinoid. The cause of a grouped or dermatomal metastatic distribution in malignant lesion is not known, but perineural lymphatic invasion and spread has been hypothesised as a possible explanation for this pattern<sup>[4]</sup>, Tumour invasion of dorsal root ganglia<sup>[5]</sup> with peripheral extension may have an important role. However acquired lymphangiectasis resembling congenital lymphangioma circumscriptum following surgical intervention and radiotherapy for malignancy can mimic grouped metastases. But histologically absence of dilated dermal lymphatic vessels in our case, ruled out this entity.

### **Conclusion :**

Our case is presented for the unusual combination of primary laryngeal squamous cell carcinoma with grouped cutaneous metastases in the neck which is not reported so far. Hence whenever we come across asymptomatic grouped lesions in an elderly person, a thorough history taking and a meticulous examination should be carried out considering a possibility of malignancy.

**Legends to photographs:**

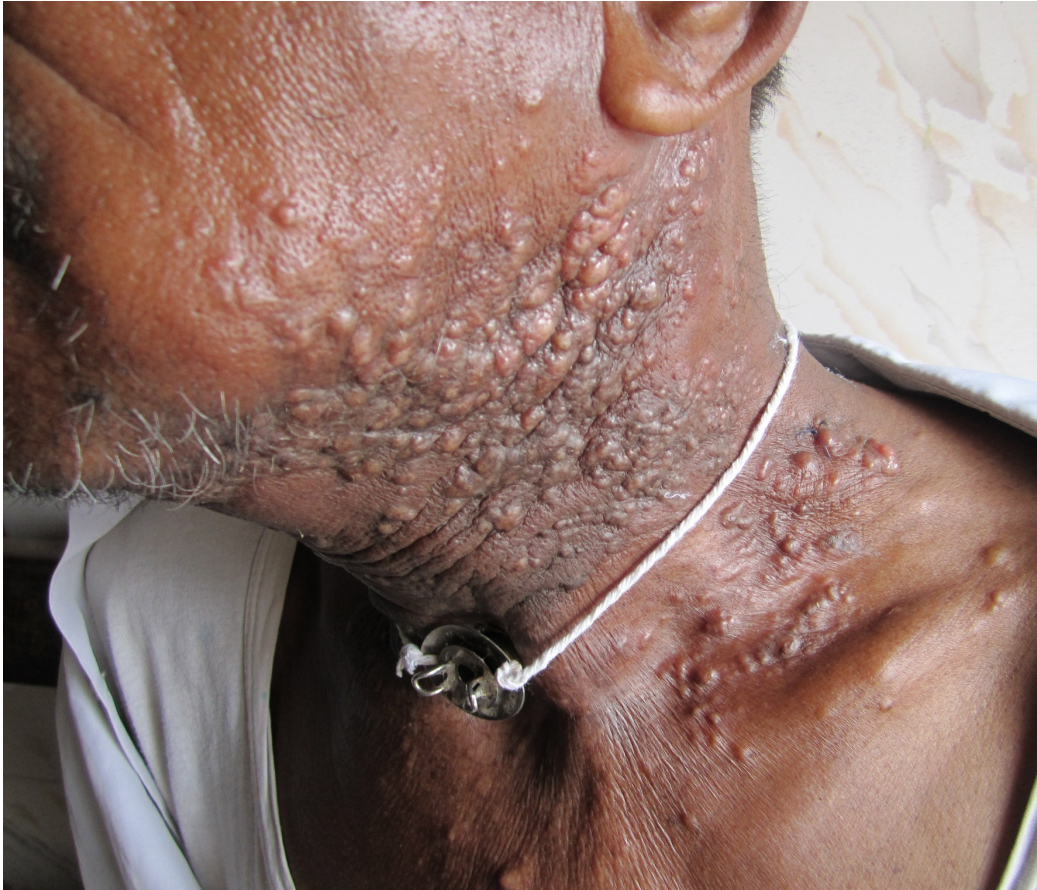

Figure 1: Asymptomatic grouped papules and nodules coalescing to form plaques over the left side of the neck

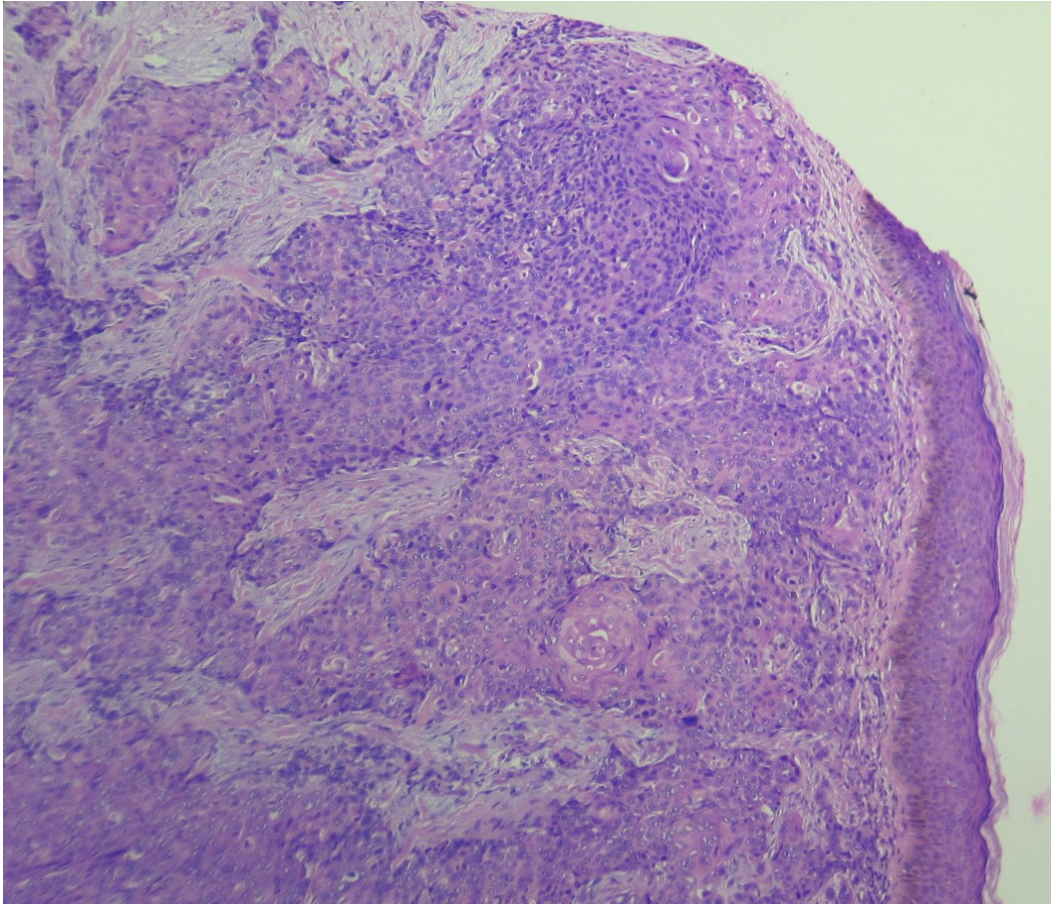


Figure 2: Histopathology revealing extensive invasion of dermis by groups of tumour cells (H&E; 10 X)



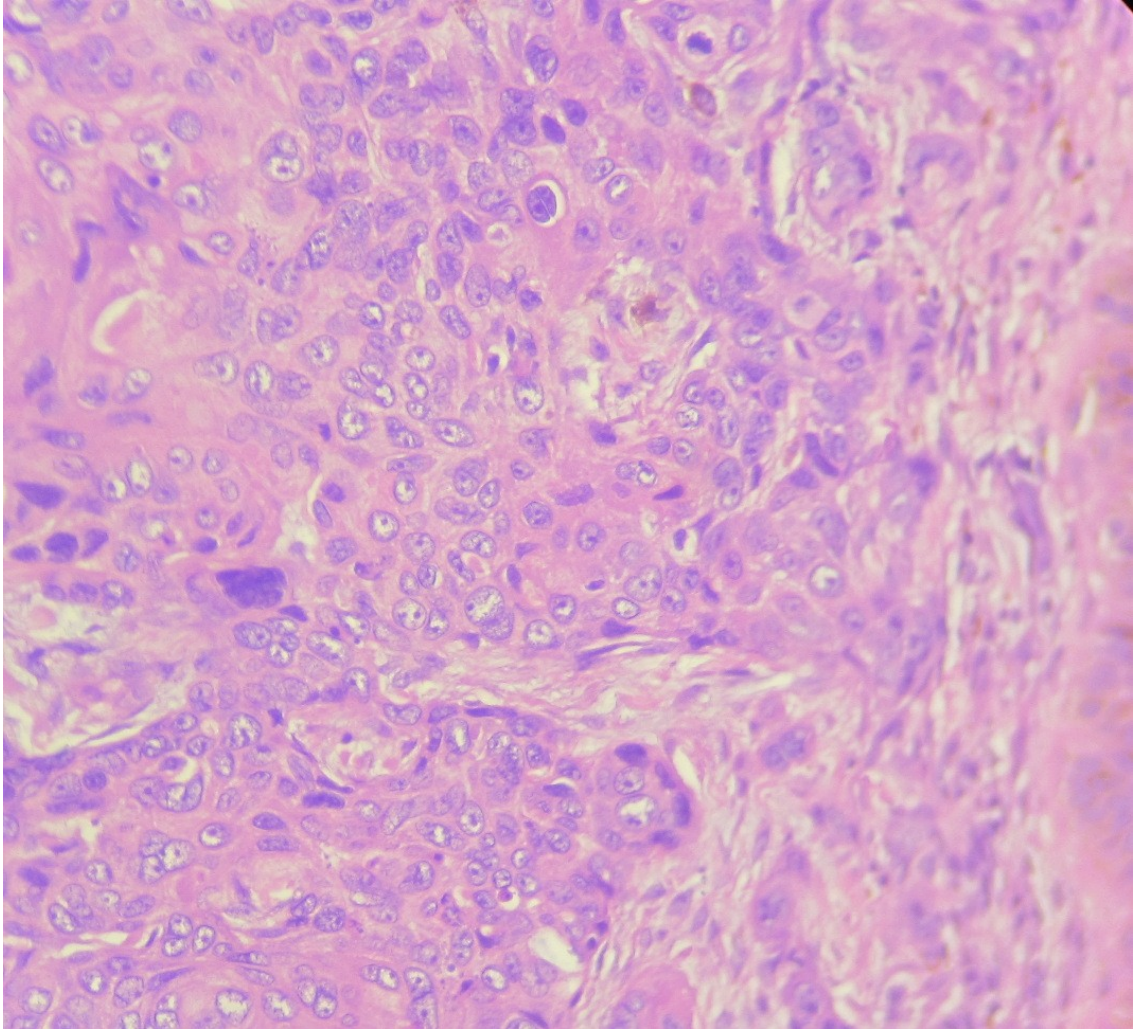


Figure 3: Atypical cells with large, pleomorphic, hyperchromatic nuclei with halo

(H&E; 10 X)

**References:**

1. Cuq-Viguié L, Viraben R. Zosteriform metastases from squamous cell carcinoma of the stump of an amputated arm. Clin Exp Dermatol. 1998 May;23[3]:116-8.
2. Sadollah Shamsadini MD, Aliakbar Taheri MD, Shahriar Dabiri, Kerman Farshid Darvish Damavandi, and Siamak Salahi. Grouped skin metastases from laryngeal squamous cell carcinoma and overview of similar cases. Dermatology Online Journal 9(5):27
3. Narendra kumar, Anjan Bera, Ritesh Kumar, Sushmita Ghoshal, Shabab Lalit Angurana, Radhika Srinivasan. Squamous cell carcinoma of supraglottic larynx with metastasis to all five distal phalanges of left hand. Indian J of Dermatol 2011; 56:578-80
4. Hodge SJ, Mackle S, Owen LG: Zosteriform inflammatory metastatic carcinoma. Int Dermatol 1979 Mar;18(2):142-5.
5. Jaworsky C, Bergfeld WF: Metastatic transition cell carcinoma mimicking zoster sine herpete. Arch Dermatol 1986 Dec;122(12):1357-8.