

Pseudotumoral Crohn's disease in an elderly patient.

Selem Bouomrani*, Nessrine Belgacem, Safa Trabelsi, Najla Lassoued, Hassen Baïli, Maher Béji

Department of Internal Medicine, Military Hospital of Gabès, Tunisia

Abstract

Crohn's disease is a very rare inflammatory cryptogenic bowel disease in the elderly and its pseudotumoral form is exceptional. We herein report a case of a pseudotumoral presentation mimicking colon cancer in an elderly patient of 75 years without significant medical history which was explored for bloody diarrhea. Colonoscopy and CT scan concluded in the presence of an ulcerated tumor of the right colon without distant metastases. The patient was operated with the diagnosis of colon cancer but histological examination showed very inflammatory ileal and colonic mucosa with many aphthous ulcers, and chronic granulation but without malignancy. Subsequent endoscopic explorations with biopsies confirmed the diagnosis of ileocecal Crohn's disease. The patient was treated with systemic corticosteroids and azathioprine with favorable outcome. At five years follow-up now, evolution is still favorable.

Keywords: Crohn's disease, Pseudotumor, Cancer, Elderly.

Accepted on December 27, 2016

Introduction

Inflammatory bowel diseases (IBD) are rare in the elderly over 60 years: their incidences are estimated at 4.5/100,000 for ulcerative colitis (UC) and 3.5/100,000 for Crohn's disease (CD) [1]. These diseases typically occur in young adults but we estimate 10% to 15% of IBD to occur after the age of 60 [2]. For example, in the Dutch population, epidemiological study noted that the incidence of older-onset Crohn's disease increased from 11.71 per 100,000 persons to 23.66 per 100,000 persons between 1991 and 2010. Because of this elevated frequency and the aging of population worldwide, authors propose a new entity called "Elderly onset inflammatory bowel disease (EO/IBD)" [3]. The diagnosis and management of these forms of the elderly presents a real challenge for the clinician [3,4]. In advanced age, inflammatory cryptogenic bowel diseases are known to have a non-benign disease course, in fact in a systematic search analysing findings from 43 studies, pooled analyses showed that older-onset CD patients were more likely to have colonic location of the disease and a very inflammatory behavior [5].

Pseudotumoral forms of these diseases are exceptional [6,7], and often very difficult to distinguish from malignant intestinal pathology especially since the IBD of the elderly seems to be associated with increased risk of malignancies, particularly colitis-associated colorectal cancer and malignant lymphoproliferative disorders [8,9]. We report a case of pseudotumoral Crohn's disease taken for a colic cancer in an elderly patient.

Case Report

Patient of 75 years with no significant medical history was explored for bloody diarrhoea with weight loss lasting for around six months. Physical examination revealed no obvious abnormalities other than acro-facial vitiligo. The clinical presentation was complicated, the morning of his admission, of a subocclusive syndrome. Laboratory tests showed inflammation (normochromic normocytic anaemia of 10 g/dl, erythrocyte

sedimentation rate at 100 mm/H1, and polyclonal hypergammaglobulinemia of 18 g/l). CT scan showed the presence of an irregular, ulcerated, and obstructive tumoral process of the right colon without distant metastases. The diagnosis of an occlusive colon cancer was made and the patient was underwent emergency surgery with right hemicolectomy (Figure 1). Histological examination of the surgical specimen showed a very inflammatory and thickened ileal and colonic mucosa with many aphthous ulcers and the presence of several types of benign hyperplastic widely ulcerated polyps replaced by a chronic granulation tissue rich in neovessels and polymorphous inflammatory cells. No signs of malignancy were detected. The histological aspect was that of a highly progressive Crohn's disease. The patient was treated with systemic corticosteroids and azathioprine at full doses with a favourable outcome. Subsequent endoscopic explorations with biopsies confirmed the diagnosis of ileocecal Crohn's disease. After 5 years of follow-up, the evolution is still favourable.

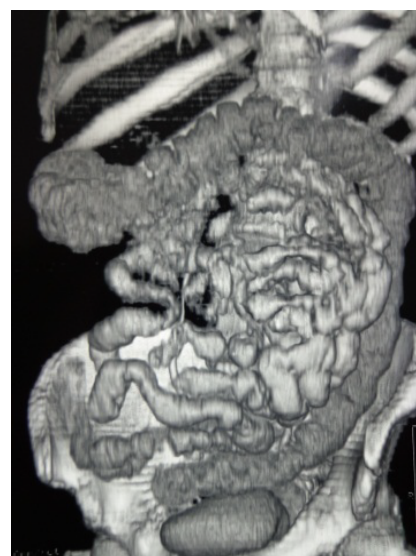


Figure 1. Abdominal CT scan with three-dimensional reconstruction showing an irregular colic thickening extended from right colon to the cecum.

Discussion

It is currently estimated that 10% to 30% of subjects with IBD (UC and CD) are aged over 60 years but only less than 15% of these diseases begin after the age of 60 [2]. The forms diagnosed for the first time in elderly people are rare and are dominated by UC [2,10,11]. They often raise the issue of differential diagnosis with other types of 'colitis in the elderly' [10]. Pseudotumoral forms are exceptional and often mistaken for colic and/or small bowel neoplasia leading to a major and mutilating surgery [6,11] (Figure 2).

This form of CD has been reported to occur mainly in young adult: a mean age of 38 years in the series of Tamzaourte et al. [12], and a mean age of 43 years in the series of Fekih et al. [7].

The clinical presentation of the pseudotumoral CD is variable: dysenteric syndrome and weight loss like our case and the case of Maamouri et al. [13], obstruction and pseudo-obstruction (secondary complication in our case) [7,12], rectal bleeding [14], abdominal mass [12,15], and fever along with acute right iliac fossa pain [7].

Radiological investigations are not contributory to the diagnosis of these pseudotumoral forms. They fail to differentiate them from colonic neoplasms. Definitive diagnosis is made by histological examination [7,12,15].

In fact, and like in our case, all the 16 patients in the series of Fekih et al. [7], and the 8 patients in the series of Tamzaourte et al. [12] underwent surgery and only the histopathological examination of surgical specimen confirmed the diagnosis of Crohn's disease (Figure 3).

Usually, this form of CD seems to be minimally aggressive and respond well to medical therapy. Indeed, Maamouri et al. had mentioned in their case a clinical remission after a local treatment with one gram per day of aminosalicylates [13]. Mnif et al. had also described a lesions regression after two months of systemic corticosteroids [14].

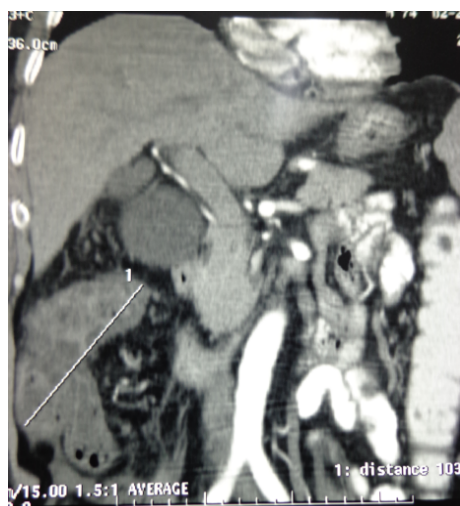

Figure 2. Abdominal CT scan with three-dimensional reconstruction showing tumoral obstruction of the right colonic with infiltration of mesenteric fat.

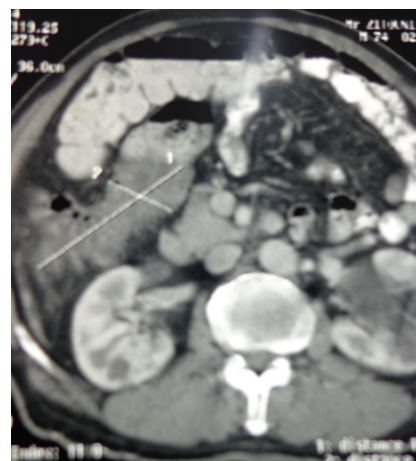


Figure 3. Axial abdominal CT scan showing irregular and obstructing tumoral process of the right colon extended to the cecum.

Conclusion

This particular form of Crohn's disease deserves to be well known as it is the main differential diagnosis with enterocolic cancers. Considering this possible diagnosis, particularly in the elderly, we can avoid a heavy and unnecessary surgery.

References

1. Piront P, Louis E, Latour P, et al. Epidemiology of inflammatory bowel diseases in the elderly in the province of Liège. *Gastroenterol Clin Biol*. 2002;26:157-61.
2. Gisbert JP, Chaparro M. Systematic review with meta-analysis: inflammatory bowel disease in the elderly. *Aliment Pharmacol Ther*. 2014;39:459-77.
3. Jeuring SF, Heuvel VTR, Zeegers MP, et al. Epidemiology and long-term outcome of inflammatory bowel disease diagnosed at elderly age-an increasing distinct entity? *Inflamm Bowel Dis*. 2016;22(6):1425-34.
4. John ES, Katz K, Saxena M, et al. Management of inflammatory bowel disease in the elderly. *Curr Treat Options Gastroenterol*. 2016;14(3):285-304.
5. Ananthakrishnan AN, Shi HY, Tang W, et al. Systematic Review and Meta-analysis: Phenotype and clinical outcomes of older-onset inflammatory bowel disease. *J Crohns Colitis*. 2016;10(10):1224-36.
6. Langeron P. Crohn's disease of tumoral form. Right hemicolectomy. *J Sci Med Lille*. 1960;78:34-9.
7. Fekih M, Cheikh M, Laabidi A, et al. Pseudotumoral colonic form of Crohn's disease: A series of 16 cases. *J Crohn's Colitis*. 2013;7: S75.
8. Taleban S, Elquza E, Gower-Rousseau C, et al. Cancer and inflammatory bowel disease in the elderly. *Dig Liver Dis*. 2016;48(10):1105-11.
9. Cheddani H, Dauchet L, Fumery M, et al. Cancer in elderly onset inflammatory Bowel disease: A population-based study. *Am J Gastroenterol*. 2016;111(10):1428-36.
10. del Val JH. Old-age inflammatory bowel disease onset: A different problem? *World J Gastroenterol*. 2011;17:2734-9.

11. Audier M, Simonin R, Payan H, et al. Pseudotumoral ileocolic form of Crohn's disease and gonadal agenesis. *Mars Med.* 1962;99:704-7.
12. Tamzaourte M, Krami H, Errabih I, et al. Pseudo-tumoral Crohn's disease: About 8 cases. *Arab J Gastroenterol.* 2009;10:AB19.
13. Maamouri N, Guellouz S, Belkahla N, et al. Chronic inflammatory disease of the intestine in its pseudo-tumor regressing under aminosalicylates. *Acta Endosc.* 2011; 41:301-302.
14. Mnif L, Boudabbous M, Chtourou L, et al. Colonic Crohn's disease in its pseudo-tumorous form. *Acta Endosc.* 2013;43:33-4.
15. Stoica T, Laky D, Stadnicov O, et al. Colonic localisation of Crohn's disease following a recurrent pseudotumor of the abdominal wall (problems of pathogenesis and therapy). *Rev Chir Oncol Radiol ORL Oftalmol Stomatol Chir.* 1980;29:41-44.

***Correspondence to:**

Selem Bouomrani
Department of Internal medicine
Military Hospital of Gabès
Tunisia
Tel: +00216 98977555
E-mail: salembouomrani@yahoo.fr