

## **Analysis on the expression level of serum MMP-7 in patients with abdominal aortic aneurysm accompanied by hypertension and clinical efficacy of endovascular graft exclusion.**

**Dezhi Liu<sup>1#</sup>, Hui Zhao<sup>2#</sup>, Boyu Liu<sup>2</sup>, Xiaokai Zhang<sup>2</sup>, Qingjie Ma<sup>1\*</sup>**

<sup>1</sup>Department of Nuclear Medicine, Sino-Japanese Friendship Hospital, Jilin University, Changchun Jilin, PR China

<sup>2</sup>Tumor Hospital of Jilin Province, Changchun Jilin, PR China

<sup>#</sup>These authors contributed equally to this work and should be considered co-first authors

### **Abstract**

**Objective:** To investigate the expression level of serum MMP-7 in patients with abdominal aortic aneurysm accompanied by hypertension and clinical efficacy of endovascular graft exclusion.

**Methods:** A retrospective analysis of 72 patients with abdominal aortic aneurysm accompanied by hypertension in our hospital was conducted. They were divided into observation group and control group with 34 and 38 cases respectively in the each group. The control group was given abdominal aortic aneurysm incision with artificial blood vessel replacement, and the observation group was given endovascular graft exclusion. During the same period, there were 72 healthy people with age and sex matched who went to our physical examination center, and 72 patients with hypertension treated in our hypertension department. ELISA method was applied to detect the serum MMP-7 expression levels in aneurysm patients accompanied by hypertensive, hypertensive patients and healthy people, who were enrolled in the study. After endovascular graft exclusion, patients' aortic aneurysm tissue and adjacent to normal artery of aneurysm were collected to conduct immunohistochemical staining to detect the expression levels of MMP-7 in aneurysmal tissue.

**Results:** ELISA assay showed that MMP-7 level of patients with aneurysm was significantly higher than that of simple hypertension patients, and the difference was statistically significant ( $P < 0.05$ ). The surgeries were successful in aneurysm patients accompanied by hypertension in the study. The operative time, blood loss and blood transfusion of the observation group were significantly less than that of the control group, and the differences were statistically significant ( $P < 0.05$ ). The Patients were followed up after surgery for one month, the overall incidence of pulmonary infection, incision infection, lower limb thrombosis, lower limb weakness and other complications in the observation group was significantly lower than that of the control group ( $P < 0.05$ ). Quality of life scores of the observation group after one month and three months were significantly higher than that of the control group, and the differences were significant ( $P < 0.05$ ). Results of immunohistochemical staining showed that MMP-7 expression level in the aneurysm tissue was significantly higher than that in adjacent to normal tissue of aneurysm. Serum MMP-7 expression levels of the two groups were significantly decreased than that before treatment, and the difference was statistically significant ( $P < 0.05$ ).

**Conclusion:** Through detecting MMP-7 expression levels in patients with hypertension has a role in early warning for the occurrence of abdominal aortic aneurysm. The application of endovascular graft exclusion for the treatment of abdominal aortic aneurysm accompanied by hypertension has minimal invasion, safety and other advantages with stable vital signs and improved life quality of the prognosis.

**Keywords:** Abdominal aortic aneurysm, Hypertension, Endovascular graft exclusion, Artificial blood vessel replacement, Matrix metalloproteinase-7 (MMP)-7.

*Accepted on September 13, 2016*

### **Introduction**

Aortic aneurysm is relatively rare in clinical practice, in which the primary abdominal aortic aneurysm account for only about 2%, although its incidence is not high, the prognosis is

relatively poor and mortality is relatively high [1]. Analysis from the onset feature shows arterial aneurysm refers to the limitations of arterial expansion with more than 50% larger than normal diameter of the artery; wherein if the abdominal aortic diameter is greater than, it is abdominal aortic aneurysm

(Abdominal Aortic Aneurysm, AAA) [2,3]. Epidemiological survey shows hypertension is a major risk factor for abdominal aortic aneurysm, and the peak age of onset is about 65 years old, which means abdominal aortic aneurysm is more among the elderly. Since the mortality of rupture caused by abdominal aortic aneurysm accompanied by hypertension reaches up to 90%, it is necessary to conduct the surgery, and there are surgical indications for the disease [4]. In the treatment methods, in 1990s, a new field of minimally invasive surgical treatment for abdominal aortic aneurysm accompanied by hypertension was initiated. It is still the standard procedure, but it has some trauma for the patients with certain serious complications for heart, lung and other organs, and relatively slow postoperative recovery. With the improvement of surgical techniques, and with the development of anaesthesia care and perioperative treatment, Endovascular Abdominal Aortic Aneurysm Repair (EVAR) has been widely used. A number of studies shows that compared with open surgery, the mortality and morbidity of endovascular treatment have reduced and endovascular treatment has its own advantages [5-7]. Although some scholars believe that the traditional procedure applies to all of the patients with abdominal aortic aneurysm below renal artery accompanied by hypertension, endovascular graft exclusion is limited by anatomical features of aneurysm neck, angulation of iliac artery, plaque of aneurysm neck, and severe calcification and important branch artery blood supply, which result in its less extensive indications [8].

Metalloproteinase-7 (Matrix Metalloproteinase-7, MMP-7) is a key enzyme for regulating the extracellular matrix decomposition process. MMP is a type of protease, which belongs to the family of matrix metalloproteinases. Its cofactor is  $Zn^{2+}$  ions regarding the extracellular matrix of type IV collagen and gelatin as the main role of the substrate. It is generally believed that MMP-7 can promote aneurysm by the degradation of the extracellular matrix [9,10].

This paper discusses the expression level of MMP-7 in patients with hypertension accompanied by abdominal aortic aneurysm.

In our hospital, we apply endovascular graft exclusion for the treatment of patients with abdominal aortic aneurysm accompanied by hypertension. The clinical results are as follows.

## Clinical Information

### Research objects

A total of 72 patients with abdominal aortic aneurysm accompanied by hypertension and 72 patients with simple hypertension who were treated in our hospital and 72 healthy people as controls from February 2013 to January 2015 were selected as research objects.

**1. Inclusion criteria of abdominal aortic aneurysm accompanied by hypertension:** Meeting the diagnostic criteria of abdominal aortic aneurysm accompanied by hypertension; palpable painless pulsating abdominal mass; aneurysm < 5 cm which patients require the treatment of infrarenal abdominal aortic aneurysm; informed consent of patients. Exclusion criteria: accompanied by severe liver and kidney disease; accompanied by mental illness; pregnant women; age < 20 years or > 80 years.

**2. Inclusion criteria of simple hypertension:** According to the 1999 WHO diagnostic criteria, measuring systolic blood pressure > 140 mmHg or diastolic blood pressure > 90 mmHg at least twice or currently taking antihypertensive medications.

Aneurysm accompanied by hypertension group was divided into two sub-groups: 38 cases in the observation group and 34 in the control group. Gender, age, tumor diameter, smoking, alcohol consumption, systolic blood pressure, diastolic blood pressure and other indexes of the two sub-groups had no significant differences ( $P > 0.05$ , Table 1).

**Table 1.** Comparison of the basic information of the two sub-groups.

Indexes	Observation group (n=34)	Control group (n=38)	Simple hypertension (n=72)	Healthy controls (n=72)	X <sup>2</sup> or t	P
Gender (M/F)	20/14	11/7	28/24	31/21	0.064	>0.05
Age	63.23 ± 2.89	63.19 ± 3.19	62.44 ± 3.28	63.47 ± 4.38	0.078	>0.05
Tumor diameter	5.56 ± 1.09	5.58 ± 1.11	-	-	0.034	>0.05
Smoking	38 (72.9%)	12 (66.7%)	26 (50.0%)	21 (40.4%)	0.043	>0.05
Alcoholic consumption	21 (61.8%)	10 (55.6%)	24 (46.2%)	20 (38.5%)	0.067	>0.05
Systolic blood pressure	159.33 ± 11.98	160.09 ± 12.78	161.3 ± 38.5	112.4 ± 13.3	20.119	<0.05
Diastolic blood pressure	97.19 ± 9.23	97.56 ± 8.91	93.4 ± 20.3	71.2 ± 10.7	19.098	<0.05

## Surgical methods

**Control group:** Abdominal aortic aneurysm incision with artificial blood vessel replacement was conducted. Under general anaesthesia, soft tissue was separated layer by layer after laparotomy and cut open posterior peritoneum to expose the abdominal aortic aneurysm; block proximal end and distal end of the aneurysm neck for the abdominal aneurysm, cut the front wall of abdominal aortic aneurysm, and ligate the openings of lumbar artery and inferior mesenteric artery. Transplant the appropriate artificial blood vessel, and restore blood flow after anastomosis; use aneurysm wall to wrap artificial blood vessel, and stitch the abdominal incision after check.

**Observation group:** Endovascular graft exclusion was applied. After local anaesthesia, the surgery was conducted in the operating room with angiography equipment. Oblique incision of the bilateral groin lengthened out to about 5 cm to reveal bilateral femoral artery; Seldinger punctured catheter to conduct abdominal aortic angiography in order to determine the feasibility of endovascular repair surgery of abdominal aortic aneurysm; if it was feasible, then appropriate stent graft was selected to place the proper position on the abdominal aorta under radiological perspective. Then the stent graft was released so that the anchoring area would closely adhere to the wall; blood flow in abdominal aorta was observed after the release of the stent graft with angiography, at last the incision of bilateral femoral artery was repaired.

## Observation target

**Perioperative indexes:** Operation time, intraoperative blood loss, volume blood transfusion and total cost of hospitalization were observed.

Criteria of successful endovascular graft exclusion-Abdominal aortic aneurysm are completely isolated with no rupture of abdominal aortic aneurysm, and blood flow is smooth in covered stent.

Criteria of successful abdominal aortic aneurysm incision with artificial blood vessel replacement-Blood flow in abdominal aorta is smooth, and blood flow in artificial blood vessel is smooth without any artificial vascular infection.

**Complications:** Complications of all the patients were observed after 1 month of operation, including pulmonary infection, wound infection, lower limb thrombosis and lower limb fatigue.

**Quality of life:** All the patients' quality of life after 1 month and 3 months of operation was investigated by SF-36 simplified scale. The total score was calculated. The higher the score was, the higher the quality of life was.

## Statistical methods

The collected data were analysed using SPSS15.0 statistical software. The measurement data were expressed with  $\bar{x} \pm s$  table. Independent-samples test was used to compare data

between groups; enumeration data were expressed with the number of cases or constituent ratio and managed by chi-square test.  $P < 0.05$  means the difference is statistically significant.

## Results

### Comparison of indexes of the two groups in perioperative period

Through observation, all patients' surgeries were successful. The operative time, volume of blood loss, volume of blood transfusion of the observation group were significantly less than that of the control group, but the total cost of hospitalization of the observation group was significantly higher than that of the control group. The differences were statistically significant ( $P < 0.05$ , Table 2).

**Table 2.** Comparison of indexes of the two groups in perioperative period ( $\bar{x} \pm s$ ).

Indexes	Observation group (n=34)	Control group (n=38)	t	P
Operation time (min)	146.34 $\pm$ 10.34	210.98 $\pm$ 15.39	6.988	<0.05
Intraoperative blood loss (ml)	50.56 $\pm$ 11.98	1000.89 $\pm$ 150.32	12.983	<0.05
Blood transfusion (ml)	100.98 $\pm$ 12.11	800.38 $\pm$ 387.38	8.397	<0.05
Total cost of hospitalization (CNY)	138023 $\pm$ 1593.98	38453.20 $\pm$ 1932.78	11.867	<0.05

### Comparison of postoperative complications

Patients were followed up for 1 month after the operation, the overall incidence rates of pulmonary infection, incision infection, lower limb thrombosis, lower limb fatigue and other complications, were significantly lower than that of the control group ( $P < 0.05$ , Table 3).

**Table 3.** Comparison of postoperative complications of the two groups.

Indexes	Observation group (n=34)	Control group (n=38)	$\chi^2$	P
Pulmonary infection	0	3	7.113	<0.05
Incision infection	1	4		
Low limb thrombosis	0	3		
Low limb fatigue	1	3		
Total	2(3.3%)	12(20.0%)		

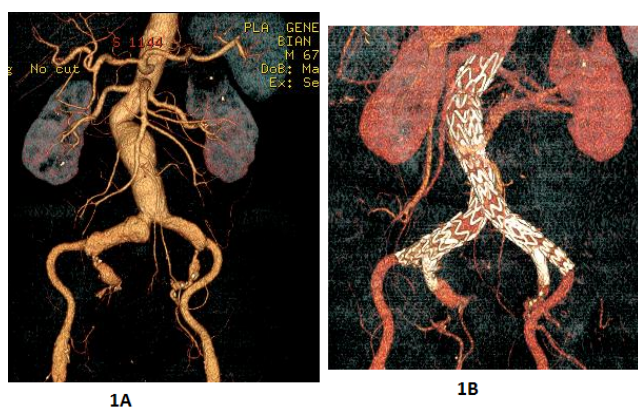
### Comparison of quality of life

After our investigation, the quality of life scores of the observation group of one month and of three months after

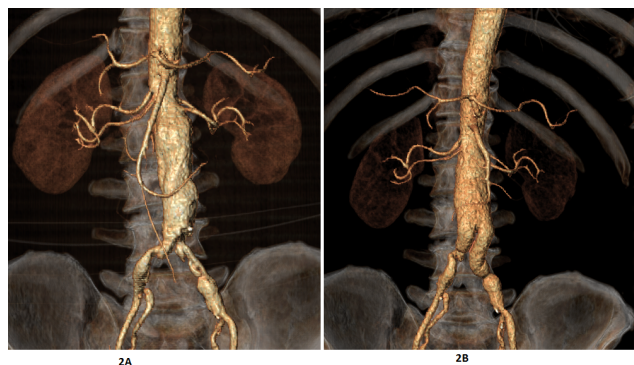
observation were significantly higher than that of the control group, and the differences were significantly ( $P < 0.05$ , Table 4).

**Table 4.** Comparison of quality of life of the two groups after operation (scores  $\pm$  s).

Indexes	Observation group (n=34)	Control group (n=38)	t	P
One month after operation	80.98 $\pm$ 3.71	67.82 $\pm$ 4.11	12.081	<0.05
Three months after operation	88.89 $\pm$ 4.21	73.29 $\pm$ 4.98	13.992	<0.05



**Figure 1.** The imaging data of endovascular graft for the treatment of abdominal aortic aneurysm accompanied by hypertension. 1A. Preoperative CT examinations showed abdominal aortic aneurysm combined with bilateral iliac aneurysm; 1B. The results of re-examination after 6 months showed the stent was in good shape with no internal leakage and bilateral internal iliac arterial patency.



**Figure 2.** The imaging data of traditional surgery for the treatment of abdominal aortic aneurysm accompanied by hypertension. 2A. Preoperative CT examination showed abdominal aortic aneurysm. 2B. The results of CT re-examination after 6 months showed the artificial blood vessel and proximal aortic anastomotic stoma and distal common iliac artery anastomosis were smooth.

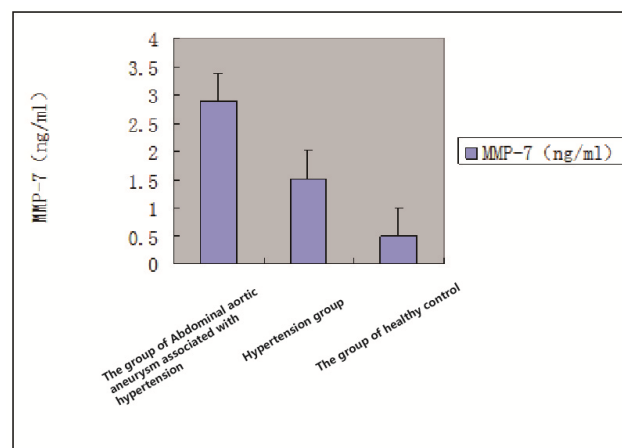
### Case analysis

CT diagnosis was carried out for the enrolled patients before and after operation. Figure 1 showed the imaging data of endovascular graft for the treatment of abdominal aortic aneurysm accompanied by hypertension. Figure 2 showed the imaging data of abdominal aortic aneurysm incision with

artificial blood vessel replacement for the treatment of abdominal aortic aneurysm accompanied by hypertension. CT showed that patients' stents were in good shape with no endoleak formation which indicated the surgery was successful.

### Expression level of MMP-7 in patients and healthy controls

In order to study the expression level of MMP-7 in patients with abdominal aortic aneurysm accompanied by hypertension, during the same periods, we collected additional 72 cases patients with simple hypertension and another 72 cases of healthy patients who experienced physical examination in our hospital. The age, gender, BMI and other basic information of the enrolled cases were matched. The results of serum MMP-7 levels in each group showed the MMP-7 level of peripheral blood of patients with abdominal aortic aneurysm accompanied by hypertension was significantly higher than that in patients with simple hypertension and healthy people. The differences were statistically significant ( $P < 0.05$ ) (Table 5 and Figure 3).



**Figure 3.** The MMP-7 level of peripheral blood of patients with abdominal aortic aneurysm accompanied by hypertension was significantly higher than that in patients with simple hypertension and healthy people. The differences were statistically significant ( $P < 0.05$ ).

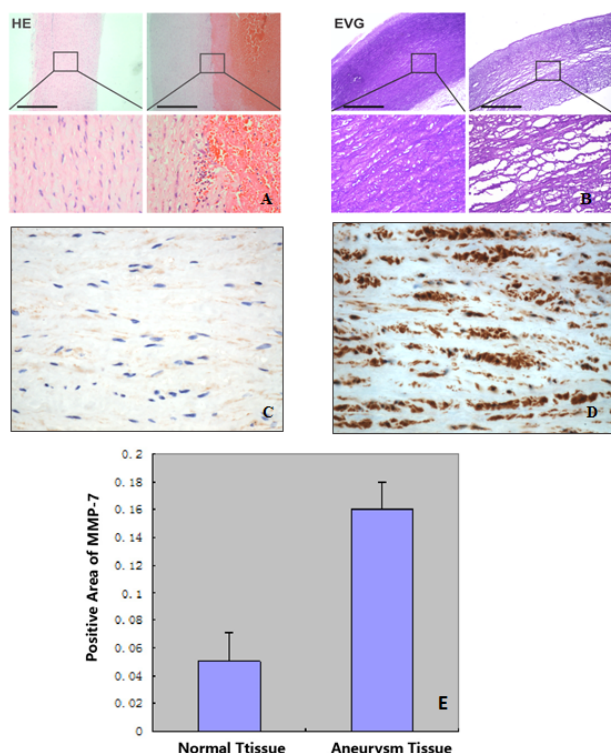
**Table 5.** Expression level of MMP-7 in patients and health controls.

Grouping	Case number	Age	BMI (kg/m <sup>2</sup> )	MAP (mmHg)	MMP-7 (ng/ml)
Group of abdominal aortic aneurysm accompanied by hypertension	72	62.1 $\pm$ 12.6	21.7 $\pm$ 1.5	113.2 $\pm$ 13.8 <sup>▲</sup>	2.887 <sup>▲</sup>
Group of simple hypertension	72	63.4 $\pm$ 13.3	22.4 $\pm$ 2.1	112.4 $\pm$ 14.6 <sup>▲</sup>	1.52 <sup>▲</sup>
Healthy controls	72	64.2 $\pm$ 10.9	21.2 $\pm$ 3.4	88.4 $\pm$ 14.3	0.5
T value		0.33	0.37	12.8	0.35
P value		0.72	0.42	0.03	0.003

Note: Compared with healthy controls  $P < 0.01$ ; Compared with healthy controls,  $\blacktriangle P < 0.01$

### **The MMP-7 expression level was increased in tissue of abdominal aortic aneurysm**

In order to further explore the expression level of MMP-7 in patients with abdominal aortic aneurysm accompanied by hypertension, we collected the tissue of aneurysm to conduct HE staining. The results of elastic fibers staining and immunohistochemical staining found MMP-7 in the tissue of aortic aneurysm was significantly increased which was significantly higher than that in the normal tissue adjacent to aneurysm. The differences were statistically significant ( $P < 0.05$ ) (Figure 4).



**Figure 4.** A, B. HE staining and elastic fiber staining showed that TAD sample of the patients showed abdominal aorta wall invaded and elastic fiber broke. C, D. The positive area of MMP-7 in the tissue of patients with abdominal aortic aneurysm accompanied by hypertension was significantly higher than that in the normal tissue adjacent to aneurysm. The difference was statistically significant ( $P < 0.05$ ).

### **Discussion**

Abdominal aortic aneurysm accompanied by hypertension is a serious life-threatening disease which is a serious incident. If allowed to progress, the disease will eventually lead to death because of ruptured aneurysm. Therefore early intervention is necessary. Although the techniques of surgery and anaesthesia have been improving, the treatment is still a problem faced by clinicians [9].

In surgical treatment, due to the big trauma and relatively large number of factors of abdominal aortic aneurysm incision with artificial blood vessel replacement, there are many disadvantages in clinical application [10]. Under the dynamic monitoring of imaging, endovascular graft exclusion for the treatment of abdominal aortic aneurysm introduces the right femoral artery stent graft into the abdominal aorta to allow stent graft to cover the proximal and distal aneurysm neck of abdominal aortic aneurysm. Since the abdominal aortic aneurysm wall in blood vessel is cut off with the blood flow and the blood flow is fluent in the stent graft, therefore abdominal aortic blood flow patency is maintained [11]. From the perspective of perioperative indicators, the surgeries of all the patients in our study were successful. The operative time, volume of blood loss and volume of blood transfusion of the observation group were significantly less than that of the control group. The total cost of hospitalization of the observation group was significantly higher than that of the control group. The differences were statistically significant ( $P < 0.05$ ). It showed that endovascular surgery can significantly reduce the blood loss and blood transfusion during operation, and could significantly save hospitalization time. It also indicated little disturbance to the circulatory system, and it not only had minimal invasion on the human body, but also reduced the risk of transfusion complications. Meanwhile, the vital signs of patients in the observation group were more stable, and patients' general conditions recovered rapidly, which reflected the unique advantages of endovascular graft surgery. But the disadvantage was that the cost was high which could be reflected in clinical promotion [12,13].

For the complications, patients were followed up for 1 month. The results showed that the overall incidence rates of pulmonary infections, incision infection, lower limb thrombosis, lower limb fatigue and other complications of the observation group were significantly lower than that of the control group ( $P < 0.05$ ). The main reasons were that for the observation group, the surgery was minimal invasive and hospitalization was short, therefore the incidence of complications was reduced. But the surgical procedure also needed to be paid attention to, and the operation time should be reduced as far as possible, especially the aortic cross-clamping time, in order to minimize infection. The examination of aortic CT angiography or magnetic resonance angiography could show endovascular aortic pathological changes, so as to provide a reference for the initial surgical protocols, and the diameter and length of selected stent [14]. During the release of the stent graft, in order to prevent the movement of it impacted by the high-speed blood flow, blood pressure should be controlled to lower before the release of the stent graft. Upon the release of the covered stent graft, it was recommended to promote the use of stent graft whose distal end had better compliance than the proximal end and distal diameter was smaller than the proximal end [15].

In our study, we found that the use of endovascular graft exclusion for the treatment of abdominal aortic aneurysm received good treatment effects. The operative time (min), blood loss (ml), blood transfusion (ml), and total cost of



hospitalization (CNY) were significantly lower than that of the group applying abdominal aortic aneurysm incision with artificial blood vessel replacement. After surgeries patients were followed up for one month. The overall incidence rates of pulmonary infection, incision infection, lower limb thrombosis, lower limb fatigue and other complications of the observation group were significantly lower than that of the control group ( $P < 0.05$ ); after 1 month and 3 months of observation, quality of life scores of the observation group were significantly higher than that of the control group. The differences were significant ( $P < 0.05$ ). These results suggested that the treatment effects and costs of endovascular graft exclusion were significantly superior to that of abdominal aortic aneurysm incision with artificial blood vessel replacement. We believe that compared with traditional open surgery, endovascular graft exclusion is a minimally invasive surgery without thoracotomy, blood loss is significantly reduced during surgery, the disordered coagulation system caused by bleeding and the massive release of inflammatory factors caused by trauma, and the prognosis of patients are significantly improved, especially for elderly patients, combined with other cardiovascular diseases and other diseases, the perioperative conditions are significantly improved [16].

SF-36 scale is also called health survey scale which is commonly used to investigate the quality of life in patients undergoing surgery. It can evaluate the effect of surgery mainly by analysing mental and physical health of patients, and it has been widely used in the evaluation for health status [16,17]. The quality of life scores of patients in the observation group after 1 month and 3 months of operation are significantly higher than that of the control group, and the difference is significant ( $P < 0.05$ ).

MMP, as proteolytic enzyme, is dependent to metal zinc ion. It plays an important role in degrading ECM, regulating many soluble factors and reconstructing tissue. It is also closely related to the onset, invasion and metastasis of tumor. Under the body's normal physiological state, MMP and TIMP are synergetic; therefore they can regulate the regeneration of ECM to maintain the relative stability of the cells. MMP disorders can accelerate the degradation of the matrix on the barrier, or indirectly promote tumor growth metastasis and invasion by means of releasing several growth factors associated with matrix. Thus MMP has become an attractive target for cancer research and the development of anticancer drugs [17-19]. In our study, by detecting the expression level of serum MMP-7, we found that patients with abdominal aortic aneurysm whose MMP-7 were significantly higher than that of the patients with simple blood pressure and the healthy controls. Moreover, immunohistochemical staining also confirmed that MMP-7 expression level was also significantly increased in aneurysm tissues. Elastic fiber staining found that the structure of abdominal aorta was loose, abdominal aortic blood invaded and elastic fiber broke. We believe that during the onset of abdominal aortic aneurysm, MMP-7 can loosen the elastic fibers by degrading extracellular matrix, which for patients with perennial hypertension; it is more likely to cause aortic aneurysm. And MMP-7 in local damaged tissue can

enter the blood circulation. Therefore, we believe that screening MMP-7 in hypertensive patients has important significance for the early diagnosis of abdominal aortic aneurysm. In addition to the aortic aneurysm, MMPs also plays a role in tumor metastasis. Studies have shown that MMP disorders can accelerate the degradation of the matrix on the barrier, or indirectly promote tumor growth, metastasis and invasion by means of releasing several growth factors associated with matrix. Thus, MMP has become an attractive target for cancer research and the development of anticancer drugs.

However, our study also has some limitations. First, because patients with aneurysm were not common, the enrolled cases of our study is limited which is bound to cause some errors on the accuracy of the statistical data. In addition, in this study, we have not included patients with thoracic aortic aneurysm, and the mechanism of aneurysmal tissue and the increased expression level of serum MMP-7 in patients with abdominal aortic aneurysm are needed to be further verified by animal experiments.

In short, if the economic conditions allowed, endovascular graft exclusion for the treatment of abdominal aortic aneurysm accompanied by hypertension has several advantages such as safety and being minimally invasive, and patients have stable postoperative vital signs, therefore the prognostic quality of life is improved.

## References

- Peterson B, Matsumura JS, Brewster DC. Five year report of a multicenter controlled clinical trial of open versus endovascular treatment of abdominal aortic aneurysms. *J Vase Surg* 2007; 45: 389-392.
- Belenky A, Atar E, Orron DE. Endovascular abdominal aortic aneurysm repair using transvenous intravascular US catheter guidance in patients with chronic renal failure. *J Vasc Interv Radiol* 2014; 25: 702-706.
- Dake MD, Kato N, Mitchell RS, Semba CP, Razavi MK. Endovascular stent-graft placement for the treatment of acute aortic dissection. *N Engl J Med* 1999; 340: 1546-1552.
- Epstein D, Sculpher MJ, Powell JT. Long-term cost-effectiveness analysis of endovascular versus open repair for abdominal aortic aneurysm based on four randomized clinical trials. *Br J Surg* 2014; 101: 623-631.
- Koshino T, Murakami G, Morishita K, Mawatari T, Abe T. Does the Adamkiewicz artery originate from the larger segmental arteries? *J Thorac Cardiovasc Surg* 1999; 117: 898-905.
- Iwakoshi S, Ichihashi S, Higashiura W. A decade of outcomes and predictors of sac enlargement after endovascular abdominal aortic aneurysm repair using zenith endografts in a Japanese population. *J Vasc Interv Radiol* 2014; 25: 694-701.
- Amabile P, Grisoli D, Giorgi R, Bartoli JM, Piquet P. Incidence and determinants of spinal cord ischaemia in

- stent-graft repair of the thoracic aorta. *Eur J Vasc Endovasc Surg* 2008; 35: 455-461.
8. Abbas A, Hansrani V, Sedgwick N, Ghosh J, McCollum CN. 3D contrast enhanced ultrasound for detecting endoleak following endovascular aneurysm repair (EVAR). *Eur J Vasc Endovasc Surg* 2014; 47: 487-492.
9. Koskensalo S, Mrena J, Wiksten JP, Nordling S, Kokkola A. MMP-7 overexpression is an independent prognostic marker in gastric cancer. *Tumour Biol* 2010; 31: 149-155.
10. Zeng ZS, Shu WP, Cohen AM. Matrix metalloproteinase-7 expression in colorectal cancer liver metastases: evidence for involvement of MMP-7 activation in human cancer metastases. *Clin Cancer Res* 2002; 8: 144-148.
11. Eggebrecht H, Nienaber CA, NeuhAuser M, Baumgart D, Kische S. Endovascular stent-graft placement in aortic dissection: A meta-analysis. *Eur Heart J* 2006; 27: 489-498.
12. Yang G, Liu C, Li Y, Liu B, Ye W. Endovascular treatment of ruptured abdominal aortic aneurysm a clinical analysis of 13 cases. *Zhonghua Yi Xue Za Zhi* 2014; 94: 344-347.
13. Sbarzaglia P, Lovato L, Buttazzi K, Russo V, Renzulli M. Interventional techniques in the treatment of aortic dissection. *Radiol Med* 2006; 111: 585-596.
14. Lee MI, Shin WY, Choe YM. Relining technique for continuous sac enlargement and modular disconnection secondary to endotension after endovascular aortic aneurysm repair. *Ann Surg Treat Res* 2014; 86: 161-164.
15. Supsamutchai C, Wilasrusmee C, Lertsithichai P. Comparison of risk-scoring systems in predicting hospital mortality after abdominal aortic aneurysm repair. *Int J Angiol* 2008; 17: 381-385.
16. Oderich GS, Correa MP, Mendes BC. Technical aspects of repair of juxtarenal abdominal aortic aneurysms using the Zenith fenestrated endovascular stent graft. *J Vasc Surg* 2014; 59: 1456-1461.
17. Li L, Wang LX1, Xu GL, Yang F, Gao QL. Bio-informatics analysis of renal carcinoma gene matrix metalloproteinase-7. *Indian J Cancer* 2016; 53: 13-18.
18. Jakubowska K, Pryczynicz A, Iwanowicz P, Niewinski A, Maciorkowska E, Hapanowicz J, Jagodzinska D, Kemona A, Guzinska-Ustymowicz K. Expressions of Matrix Metalloproteinases (MMP-2, MMP-7, and MMP-9) and their inhibitors (TIMP-1, TIMP-2) in inflammatory bowel diseases. *Gastroenterol Res Pract* 2016; 2016: 2456179.
19. Sun Y, Li D, Lv XH, Hua SC, Han JC. Roles of osteopontin and matrix metalloproteinase-7 in occurrence, progression, and prognosis of non-small cell lung cancer. *J Res Med Sci* 2015; 20: 1138-1146.

**\*Correspondence to**

Qingjie Ma  
Department of Nuclear Medicine  
Sino-Japanese Friendship Hospital  
Jilin University  
PR China